



Common Podiatric Conditions

Caleb McFerren, DPM

Assistant Professor – Department of Orthopedics

Podiatry Division

The Ohio State University Wexner Medical Center

MedNet21
Center for Continuing Medical Education

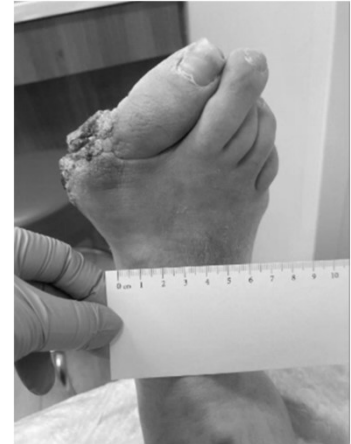 **THE OHIO STATE UNIVERSITY**
WEXNER MEDICAL CENTER

Objectives

- Discuss common podiatry conditions
- Discuss evaluation, management, and recommendations
- Bunion deformity
- Hallux limitus
- Paronychia
- Puncture wounds / foreign body
- Tinea pedis
- Critical lower extremity conditions (office)

Bunion

- Also known as hallux abductovalgus deformity
- Presents with “bump” at medial 1st metatarsal head
- Pain, inflammation, edema at 1st metatarsophalangeal joint
- Can present with callus or ulcer
- Can be asymptomatic



Bunion

Differential Diagnoses

- Gout
- Rheumatoid arthritis/Psoriatic arthritis
- Infection
- Trauma
- Arthritis

Bunion Etiology

Primary	Secondary	Trauma
Pronation	RA, Gout	Sesamoid fracture
Flexible midfoot / elevatus	2 nd toe amputation	1 st MPJ ligament instability
Elongated 1 st ray	Sesamoidectomy	Fracture of 1 st toe or 1 st metatarsal
	Limb length discrepancy	
	Neuromuscular disorders	

Derived from Textbook of Bunion Surgery. Preoperative Evaluation of the Bunion Patient. Ch. 2 Table 1. J Gebert, S. Palladino. Date Trace 2012.

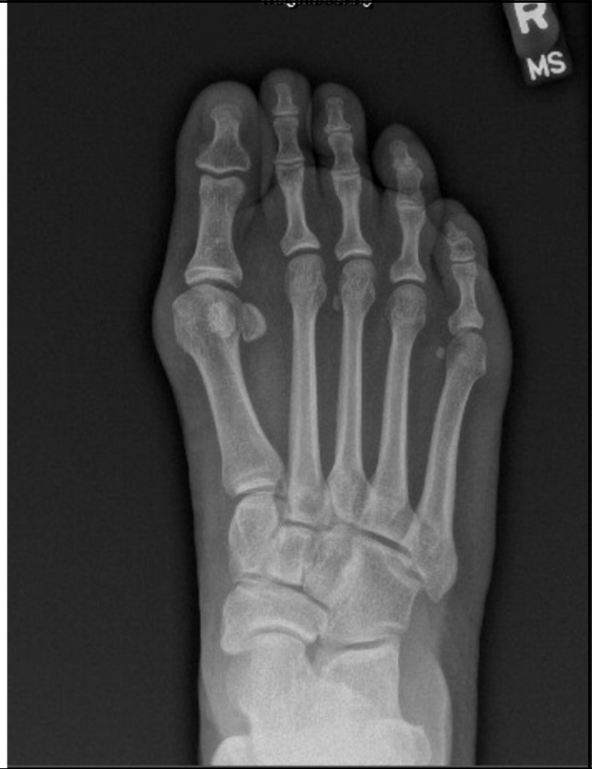Bunion physical exam

Pain with manual pressure to 1st metatarsal head

- Medial 1st metatarsal head prominence
 - Lateral deviation of 1st toe
 - Can be asymptomatic
- Weightbearing exam
- Tracking vs trackbound at 1st MPJ
- 1st MPJ range of motion
- 1st ray hypermobility?

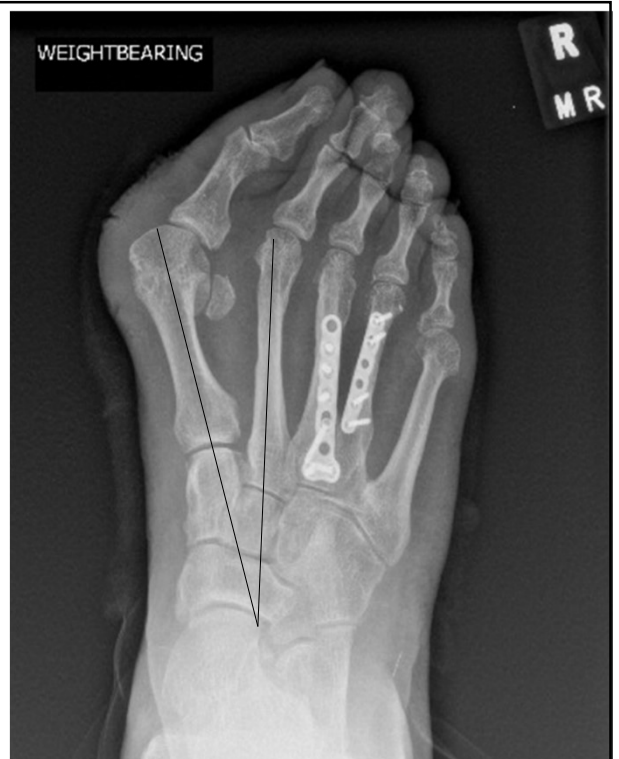Bunion radiographs

- WEIGHTBEARING***
- 1st intermetatarsal (IM) angle
- Hallux abductus angle
- Hallux abductus interphalangeus angle
- Sesamoid position
- Elevatus
- Bone quality



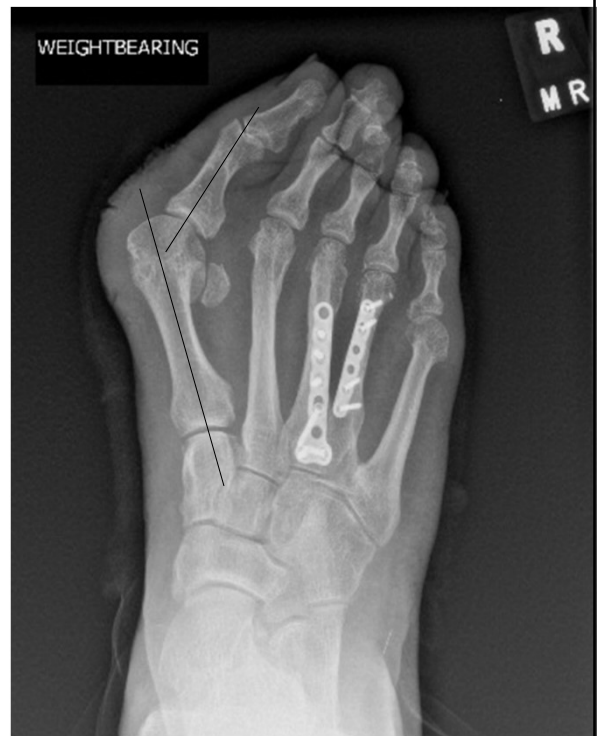Bunion radiographs

- WEIGHTBEARING***
- 1st IM angle 8-10°



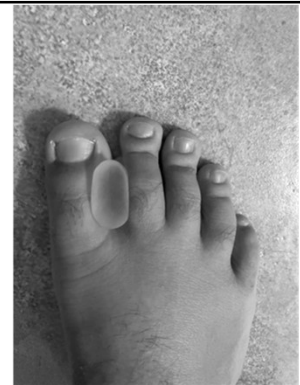Bunion radiographs

- WEIGHTBEARING***
- Hallux abductus angle 10-15°



Conservative Care

- NSAIDs
- Icing
- Bunion pads/sleeves
- Splinting
- Wide toe box shoes
- Orthotics

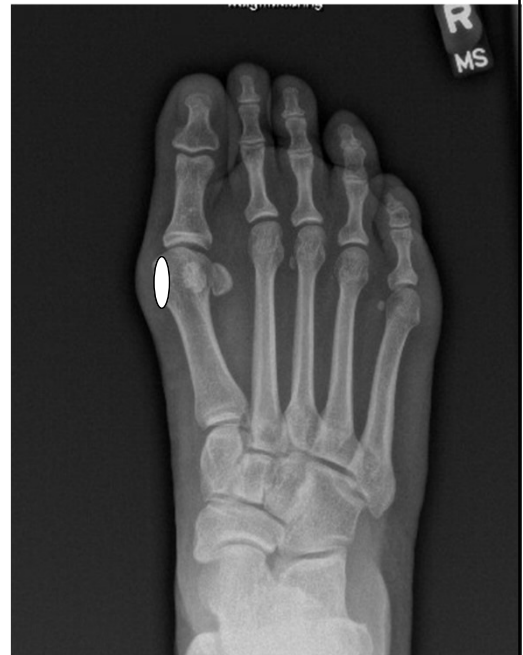

Bunion Surgical Options

- Soft tissue/bone remodel
- Osteotomy
- Fusion
- Address any other biomechanical factors
 - Ex: flatfoot deformity, equinus

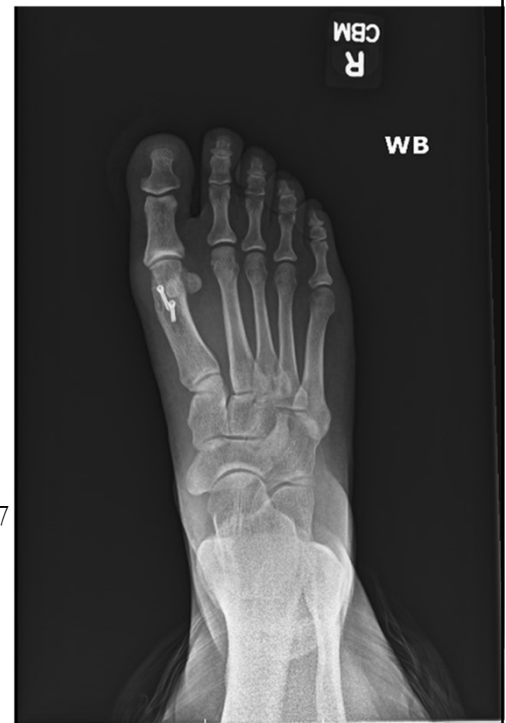Bunion Surgical Options

- Soft tissue/bone remodel
 - Silver procedure
 - Capsulorrhaphy
 - Sesamoidectomy



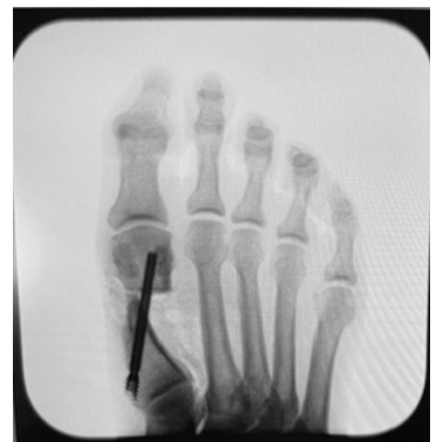Bunion Surgical Options

- Osteotomy
 - Distal ²
 - Proximal
 - Midshaft ^{4,5}
 - Proximal phalanx (Akin procedure) ⁷
 - MIS



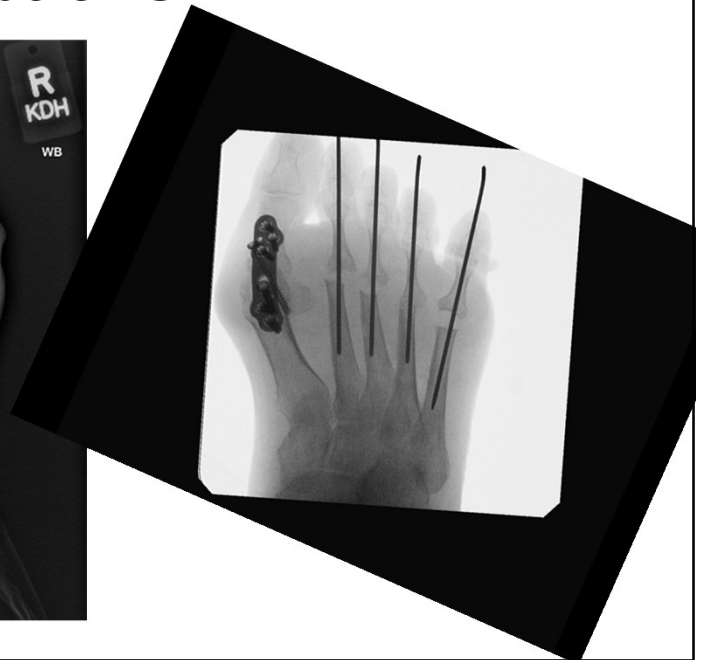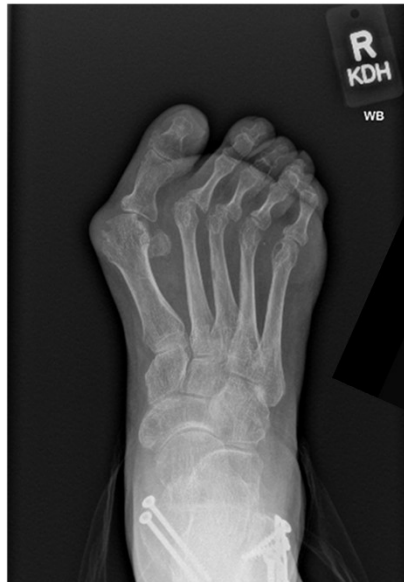Bunion Surgical Options

- Osteotomy
 - Distal
 - Proximal
 - Midshaft
 - Proximal phalanx (Akin procedure)
 - MIS ^{8,9}



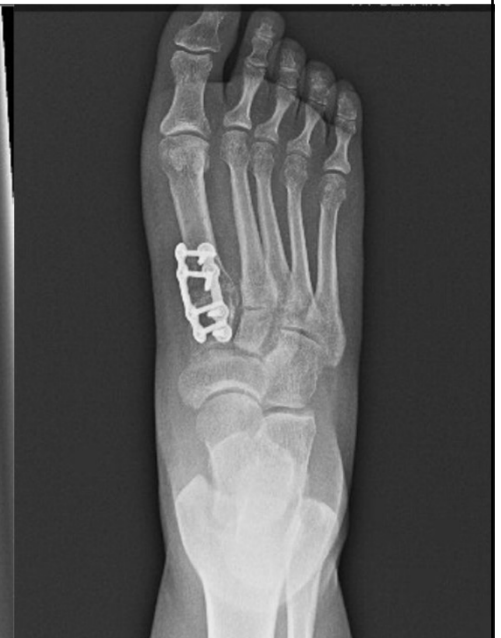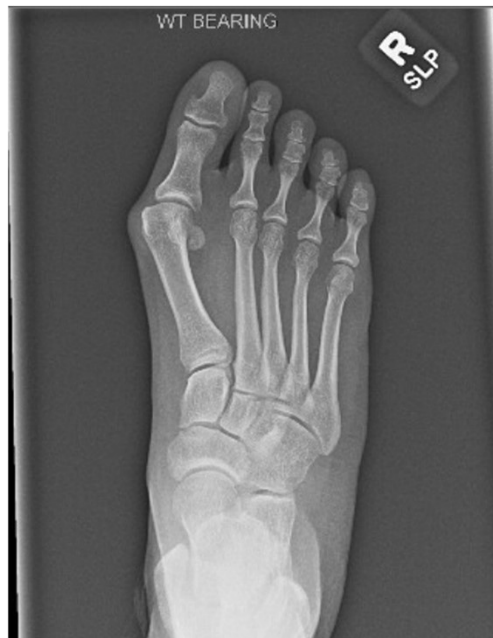
Bunion Surgical Options

- Fusion



Bunion Surgical Options

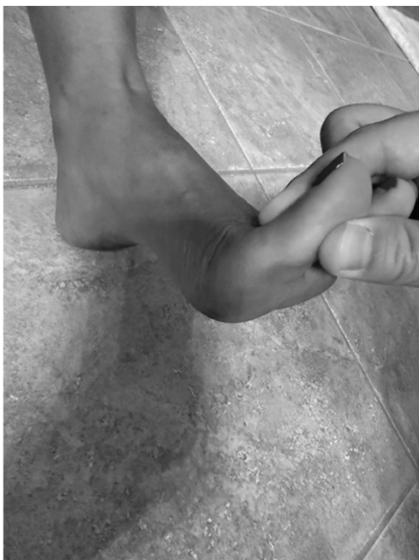- Fusion ⁶



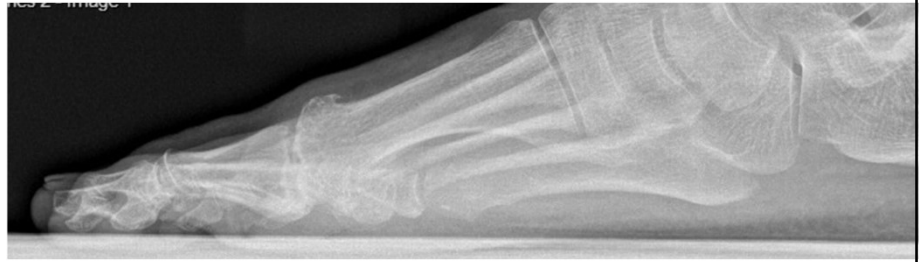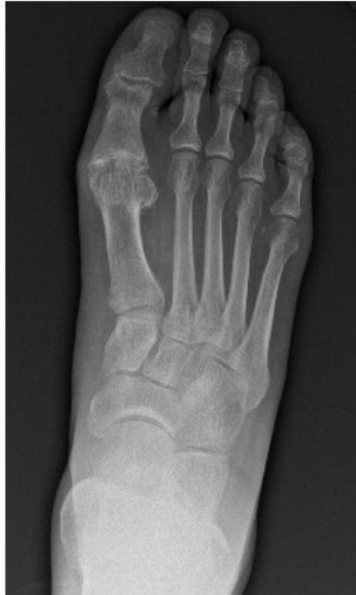Hallux limitus/rigidus

- Decreased range of motion at 1st MPJ ^{10,11}
 - Normal dorsiflexion 65°
 - Normal plantarflexion 20°
 - Hallux rigidus = less than 20° 1st metatarsophalangeal joint ROM
 - Functional hallux limitus = less than 20° 1st metatarsophalangeal joint ROM when weightbearing

Hallux limitus/rigidus



Hallux limitus/rigidus



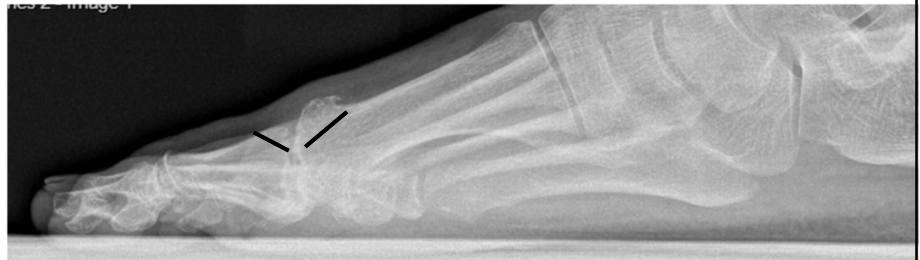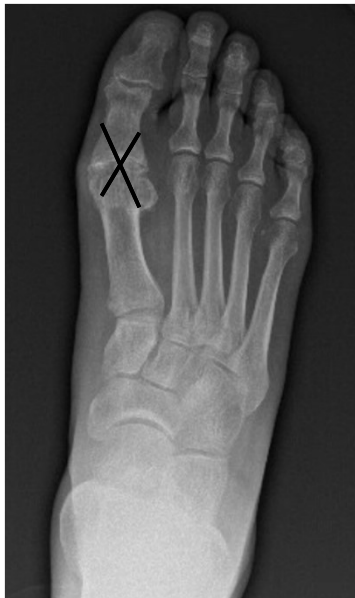Hallux limitus/rigidus

- Imaging
 - X-rays
 - MRI – osteochondral defect/cyst
 - CT

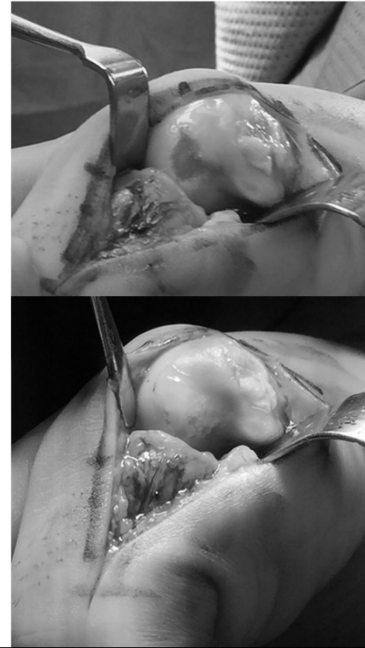
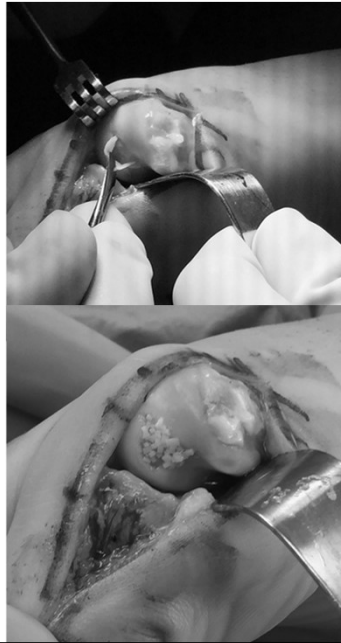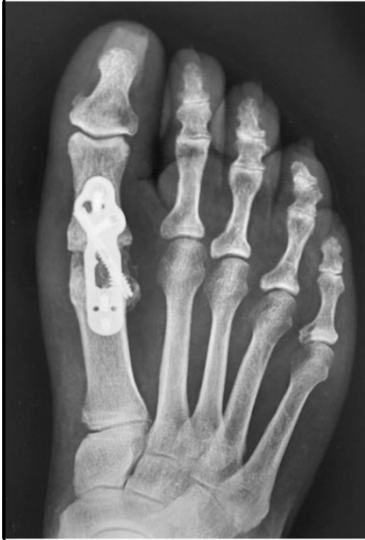Hallux limitus/rigidus - treatment

- NSAIDS
- Steroid injection
- Orthotics
 - Morton's extension
- Carbon fiber plate
- PT

Hallux limitus/rigidus procedures



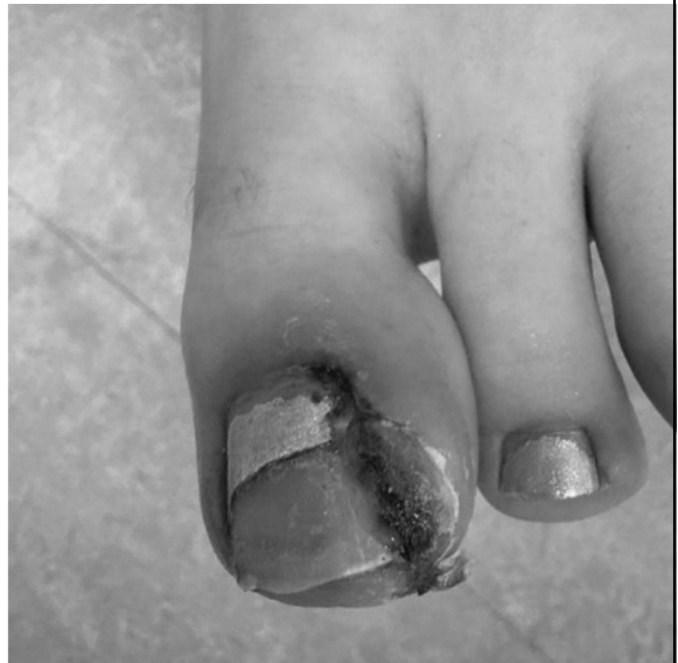Hallux limitus/rigidus procedures



Paronychia

Infected ingrown toenail ¹³

- Pain often 1st sign
- Cellulitis
- Drainage
- Check shoes
- Trauma
- Biomechanical causes



Paronychia

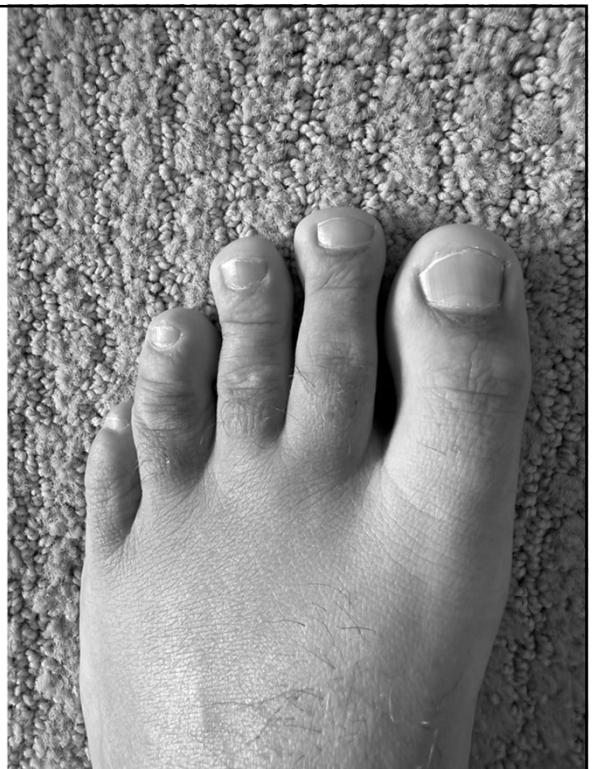
Treatment based on severity ^{14,15}

- Mild
 - Epsom salt soaks
 - Topical antibiotics
 - Tissue manipulation (cotton tip)
- Moderate
 - Oral antibiotics – Staph aureus, Streptococci, Pseudomonas
 - Nail avulsion
- Severe/neglected
 - Chronic > 6 weeks
 - Complete avulsion
 - Advanced imaging

Nail avulsion

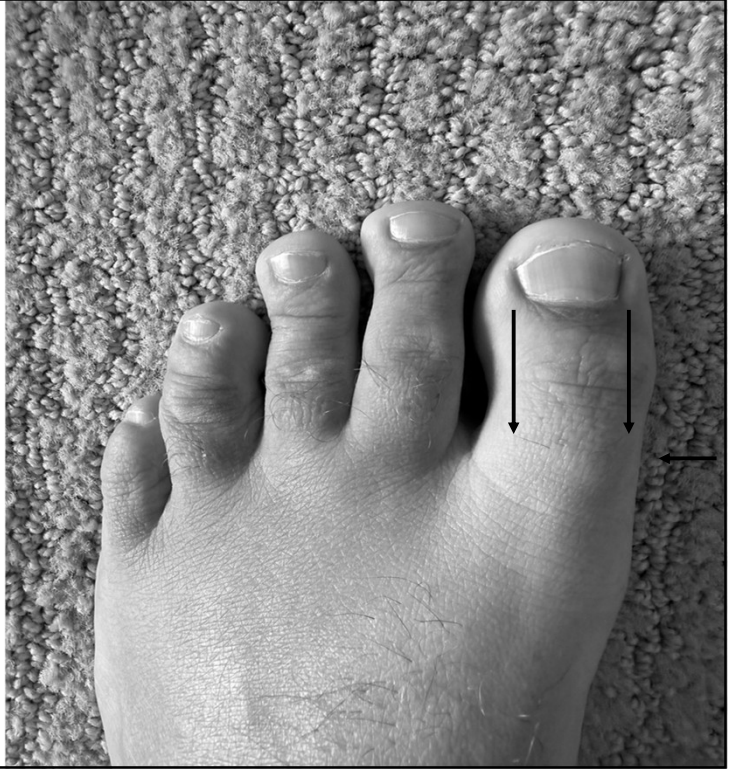
Determined by extent of infection

- Partial (medial/lateral)
- Complete avulsion
- Antibiotic considerations
 - Culture if deep infection
 - 1st generation cephalosporin
- Recurrence?
 - Matrixectomy – permanent procedure
 - Phenol vs excisional



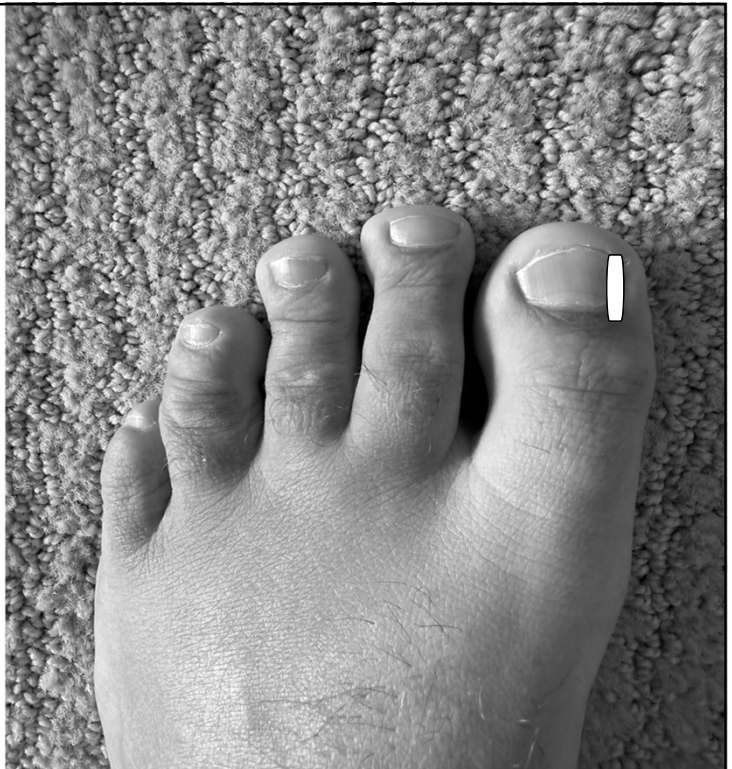
Nail avulsion

- Digital block
 - 1% lidocaine plain (2-5cc)
- Appropriate tools
 - English anvil
 - Freer
 - Curette
 - Hemostat
- Irrigate with 0.9% NS



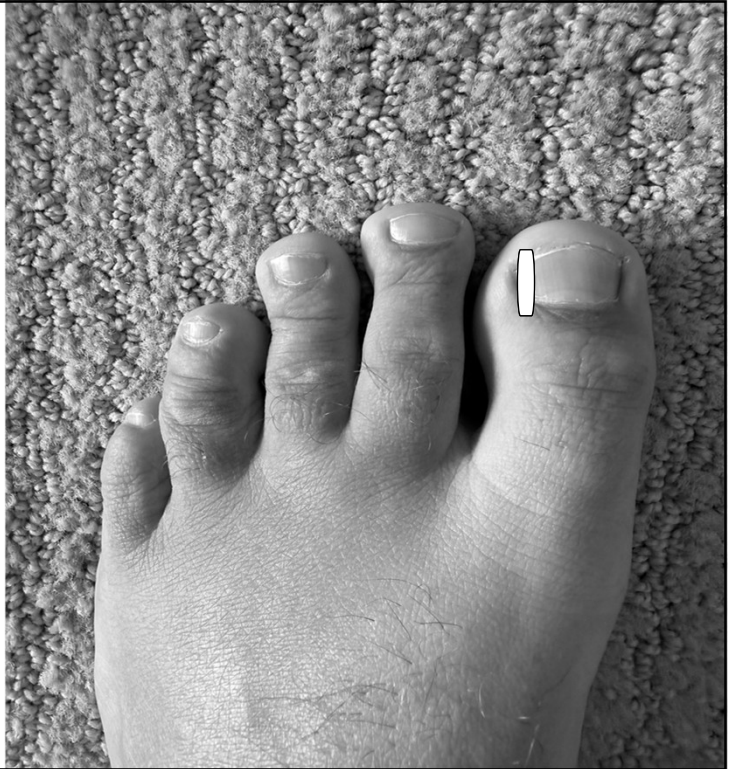
Nail avulsion

- Digital block
 - 1% lidocaine plain
- Appropriate tools
 - English anvil
 - Freer
 - Curette
 - Hemostat
- Irrigate with 0.9% NS



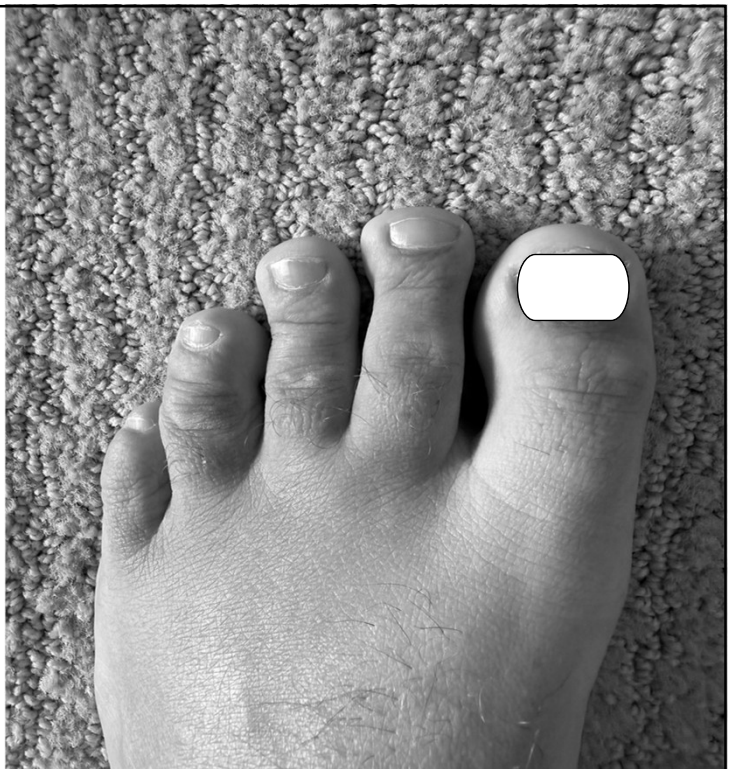Nail avulsion

- Digital block
 - 1% lidocaine plain
- Appropriate tools
 - English anvil
 - Freer
 - Curette
 - Hemostat
- Irrigate with 0.9% NS



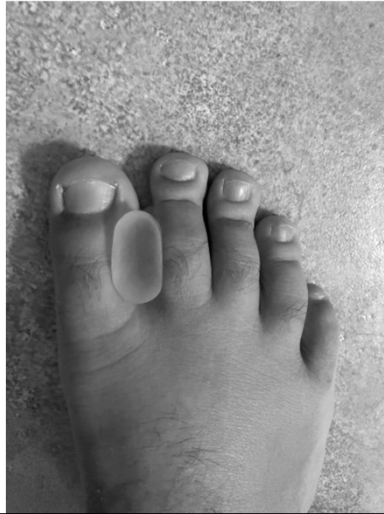Nail avulsion

- Digital block
 - 1% lidocaine plain
- Appropriate tools
 - English anvil
 - Freer
 - Curette
 - Hemostat
- Irrigate with 0.9% NS



Patient education

- Wide toe box shoes
- Toe splints
- Proper hygiene



Foreign body

- Puncture wound
- Direct extension?
- Through sock or shoe?
- Tetanus status – CDC guidelines
- Examples
 - Nail – most common
 - Glass
 - Wood

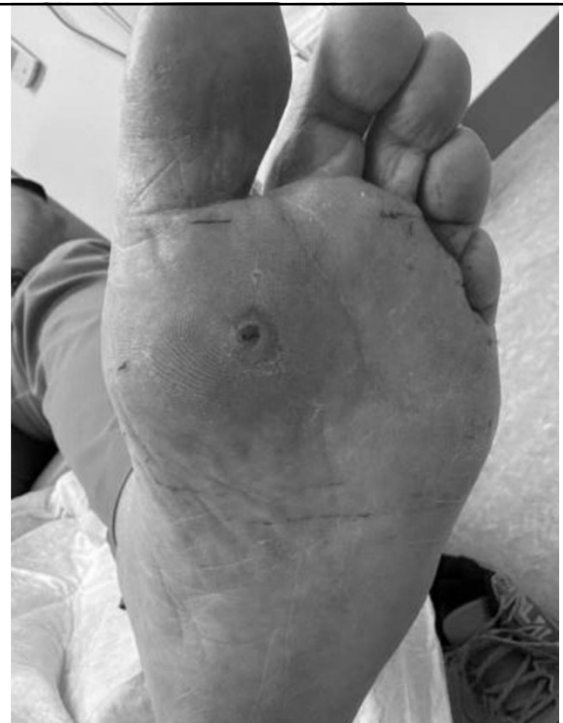Foreign body – tetanus update

Vaccination History	Tdap (clean/minor)	TIG (clean/minor)	Tdap (all other)	TIG (all other)
Incomplete/unknown	Yes	No	Yes	Yes
Complete < 5 years	No	No	No	No
Complete 5-10 years	No	No	Yes	No
Complete > 10 years	Yes	No	Yes	No

CDC 2025 Clinical Guidance for Wound Management to Prevent Tetanus

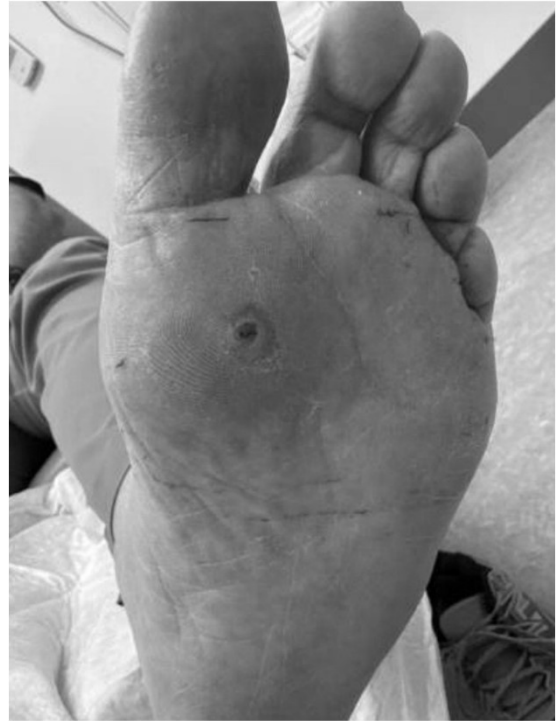Foreign body

- Anatomic considerations
- Patient and physician safety
- Cellulitis
- Wound drainage

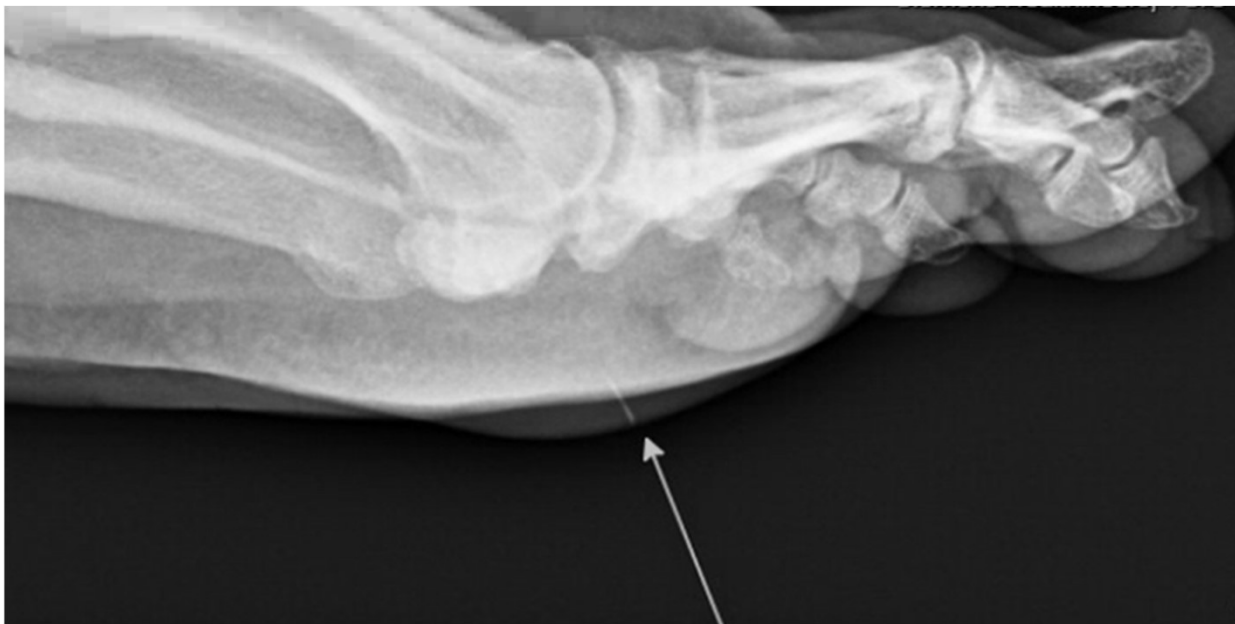

Foreign body imaging

- Helps identify depth
- X-ray***
- CT
- Ultrasound ¹⁹
- MRI
 - Drainage
 - Osteomyelitis
- Patzakis Classification ¹⁷
 - Zone 1 – toe to metatarsal head (50%)
 - Zone 2 – midfoot (17%)
 - Zone 3 – calcaneus (33%)

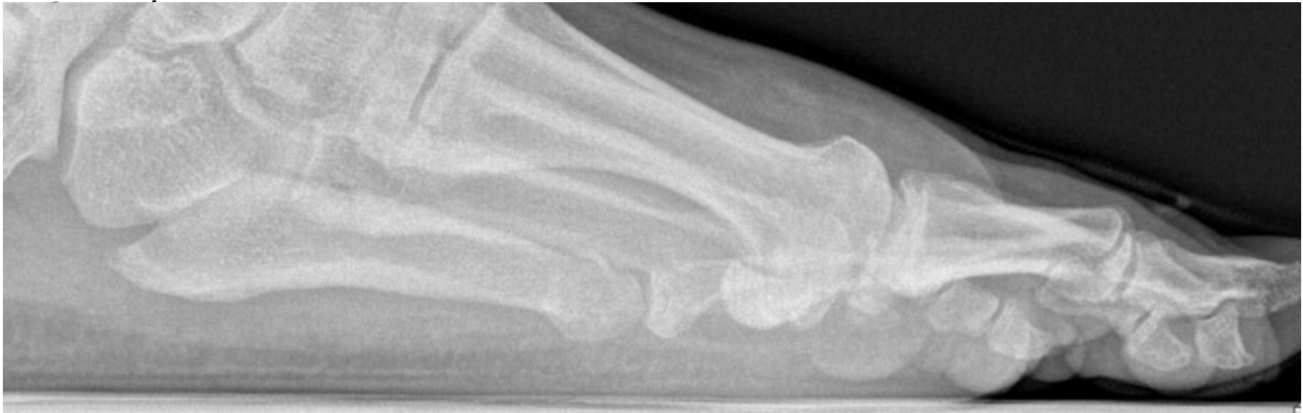

Foreign body imaging



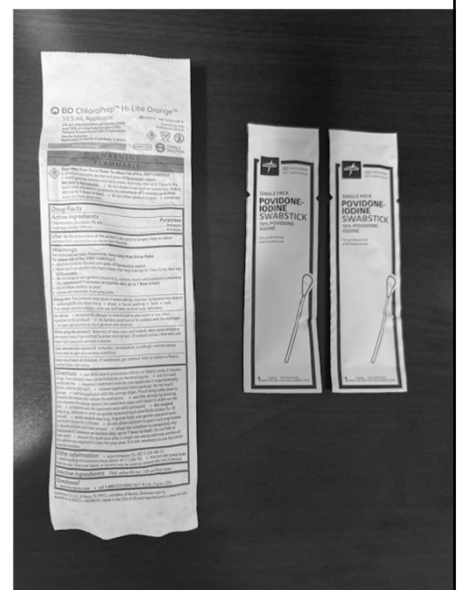
Foreign body (post removal)

- Obtain post removal imaging if possible



Foreign body management

- Superficial cleansing
- Removal of foreign body
 - In office vs OR
- Wound exploration and debridement
 - Wound culture if applicable
- Copious irrigation
- Wound care
 - Pack open
 - Insert drain
 - Appropriate dressing changes
- Offloading of wound
 - Cutout pads
 - Surgical shoe/boot



Foreign body management

Antibiotic considerations

- Staph aureus – most common
- Beta-hemolytic strep – 2nd most common
- Through sock/shoe? – consider *Pseudomonas aeruginosa* coverage
- May not need intervention
 - Young, healthy
 - Minor or superficial wound
- 1st generation cephalosporin

Tinea pedis

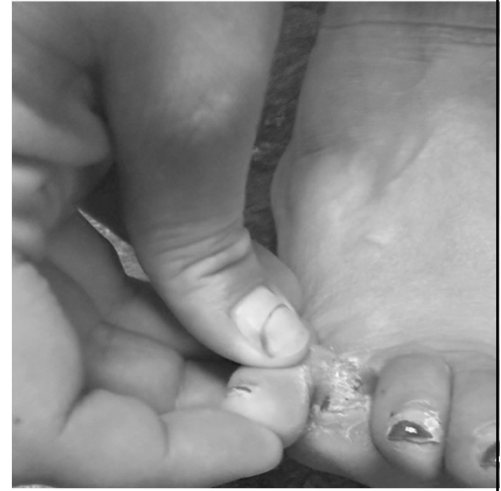“Athlete’s foot” 22

- Interdigital or moccasin type
- Shoes and socks create optimal environment
- Dry, itching scale, can be pruritic
- Differential diagnosis: eczema, psoriasis xerosis, corns/callus

Tinea pedis

Interdigital

- Maceration, possible fissure
- Can have secondary bacterial infection
 - Ex: *Pseudomonas*, *Corynebacterium*



Tinea pedis

Moccasin type

- *Trichophyton rubrum*
- Chronic form
- Serpiginous, circular scale
- Possible erythema

Tinea pedis

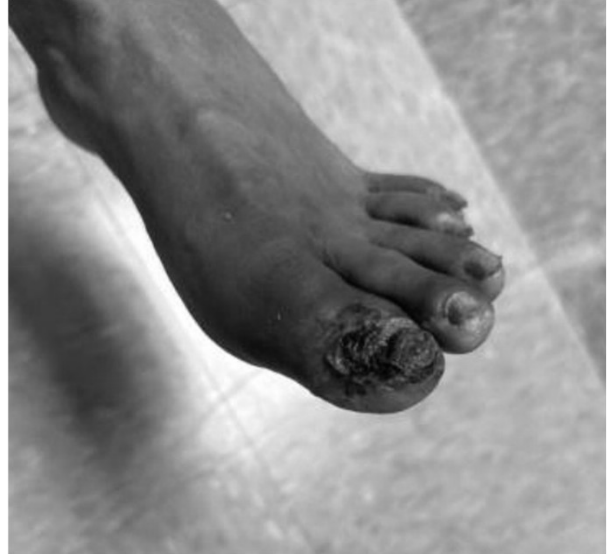- KOH (potassium hydroxide) preparation
 - +fungal hyphae
- Fungal culture, PAS stain, PCR
- Punch biopsy to rule out differential diagnoses
- Educate on proper hygiene

Tinea pedis

- Topical medications (4 weeks)
 - Ciclopirox
 - Ketoconazole
 - Econazole
 - Terbinifine
 - Naftifine
- Oral antifungal (chronic)
 - Terbinafine 250mg daily for 2 weeks
 - Itraconazole 200mg BID for 1 week
 - Fluconazole 150mg weekly for 2-6 weeks

Peripheral Arterial Disease

- Thin, atrophic skin
- Decreased/absent pulses
- Absent pedal hair
- Cool to touch
- Doppler if available



Peripheral Arterial Disease

Atherosclerotic disease with arterial obstruction

- Smoking history
- HTN
- HLD
- Family history of PAD
- Claudication
- Rest pain

Diagnostic testing - ABI

Ankle/Brachial Index – 1st line for outpatient provider

- $A/B = I$
- Ankle pressure / Arm pressure = Index
- Report will generally also show wave form and TBI
 - Triphasic = normal
- Interpret with caution
 - Ex: calcified vessels in diabetic causes false elevation
 - Defer to vascular surgeon of previous intervention (bypass)

ABI	Analysis	Risk	Recommendation
> 1.3	Elevated	Clinical picture*	Refer to vascular
0.9 – 1.3	Normal	Low	None
0.8 – 0.9	Mild PAD	Moderate/Low	Clinical picture, risk dependent*
0.5 – 0.8	Moderate PAD	Moderate/High	Refer to vascular
< 0.5	Severe PAD	High	Refer to vascular

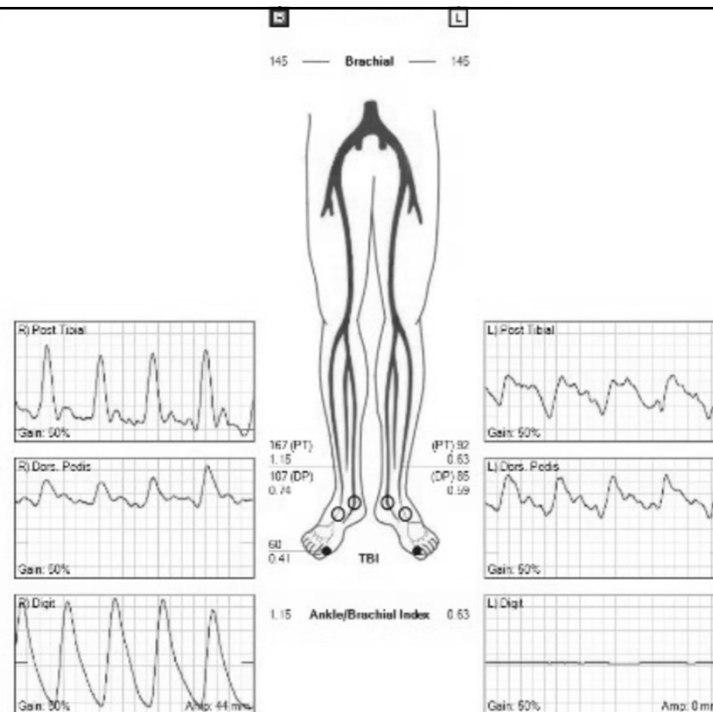
Non-invasive vascular testing

Toe Brachial Index

- TBI
- Normal > 0.70
- Severe PAD < 0.30
- If toe wound present, might not be performed

Marston et al., 2006
Mills et al., 2014

ABI



ABI

IMPRESSION

Right Lower Limb:

The ankle brachial index is within normal limits.
Biphasic waveforms noted in the posterior tibial artery and dorsalis pedis artery.
The ankle PVR is abnormal.
The great toe pressure is abnormal.

Left Lower Limb:

Moderate decrease in arterial perfusion to the lower extremity at rest.
Monophasic waveforms noted in the posterior tibial artery and dorsalis pedis artery.
The ankle PVR is abnormal.
The great toe PPG waveform is absent, unable to obtain great toe pressure.
The 2nd digit PPG waveform is abnormal.

Segment	Right				
	Pressure	Index	Waveform	PVR Waveform	PPG Waveform
Brachial	145				
Ankle (PT)	167	1.15	Biphasic	Abnormal	
Ankle (DP)	107	0.74	Biphasic		
1st Digit	60	0.41			Abnormal

Segment	Left				
	Pressure	Index	Waveform	PVR Waveform	PPG Waveform
Brachial	145				
Ankle (PT)	92	0.63	Monophasic	Abnormal	
Ankle (DP)	85	0.59	Monophasic		
1st Digit					Absent
2nd Digit					Abnormal

Non-invasive vascular testing

TcPO₂

- Transcutaneous oxygen pressure
- < 30mmHg = severely impaired arterial perfusion ²⁷
- 30 – 50mmHg = mild to moderately impaired arterial perfusion
- TcPO₂ lower specificity than skin perfusion pressure or TBI

Updated Recommendations

Circulation

Volume 149, Issue 24, 11 June 2024; Pages e1313-e1410
<https://doi.org/10.1161/CIR.0000000000001251>

CLINICAL PRACTICE GUIDELINES

2024

**ACC/AHA/AACVPR/APMA/ABC/SCAI/SVM/SVN/SVS/SIR/VES
Guideline for the Management of Lower Extremity
Peripheral Artery Disease: A Report of the American
College of Cardiology/American Heart Association Joint
Committee on Clinical Practice Guidelines**

Heather L. Gornik, MD, FAHA, MSVM, Herbert D. Aronow, MD, MPH, FACC, FSCAI, FSV, Philip P. Goodney, MD, MS, DFSVS, Shipra Arya, MD, SM, Luke Packard Brewster, MD, PhD, MA, RVT, DFSVS, FAHA, Lori Byrd, MS, Venita Chandra, MD, Douglas E. Drachman, MD, FACC, FSCAI, Jennifer M. Eaves, DNP, MSN, RN, Jonathan K. Ehrman, PhD, FACC, FAHA, AACVPR, John N. Evans, DPM, Thomas S.D. Getchius, J. Antonio Gutiérrez, MD, MHS, Beau M. Hawkins, MD, FACC, FSCAI, FSV, Connie N. Hess, MD, MHS, FACC, FAHA, FSCAI, Karen J. Ho, MD, FAHA, W. Schuyler Jones, MD, FACC, Esther S.H. Kim, MD, MPH, FAHA, FSV, Scott Kinlay, MBBS, PhD, FACC, FAHA, Lee Kirksey, MD, MBA, Debra Kohlman-Trigoboff, RN, MS, ACNP-BC, CVN, Chandler A. Long, MD, Amy West Pollak, MD, MSc, FAHA, Saher S. Sabri, MD, Lawrence B. Sadwin, Eric A. Secemsky, MD, MSc, FACC, FAHA, FSCAI, FSV, Maya Serhal, MD, FACC, Mehdi H. Shishehbor, DO, MPH, PhD, FACC, FSV, Diane Treat-Jacobson, PhD, RN, MSVM, FAHA, and Luke R. Wilkins, MD, FSIR

Aim: The "2024 ACC/AHA/AACVPR/APMA/ABC/SCAI/SVM/SVN/SVS/SIR/VES Guideline for the Management of Lower Extremity Peripheral Artery Disease" provides recommendations to guide clinicians in the treatment of patients with lower extremity peripheral artery disease across its multiple clinical presentation subsets (ie, asymptomatic, chronic symptomatic, chronic limb-threatening ischemia, and acute limb ischemia).

10 Take Home Messages from report

1. Peripheral arterial disease is a common cardiovascular disease associated with increased risk of amputation, MI, stroke, and death, as well as impaired quality of life, walking, performance, and functional status.
2. The guideline defines 4 clinical subsets of PAD: asymptomatic PAD (may have functional impairment), chronic symptomatic PAD (including claudication), chronic limb threatening ischemia, and acute limb ischemia.
3. Detection of PAD in most patient is accomplished through the history, physical, examination, and resting ankle-brachial index
4. Health disparities in PAD are associated with poor limb and cardiovascular outcomes and must be addressed at the individual patient and population levels, with interventions coordinated between multiple stakeholders across the cardiovascular community and public health infrastructure

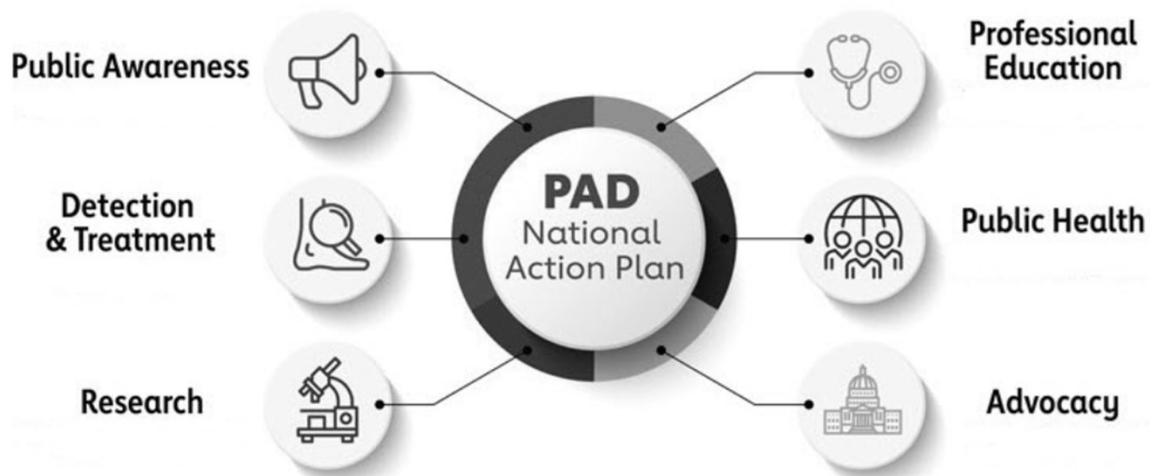10 Take Home Messages from report

5. Effective medical therapies for patients with PAD should be prescribed to prevent major adverse cardiovascular events and major adverse limb events for patients with PAD, including antiplatelet (generally single antiplatelet) and antithrombotic therapy, lipid-lowering (ie, high intensity statin) and antihypertensive therapy, management of diabetes, and smoking cessation. Rivaroxaban (2.5mg twice daily) combined with low-dose aspirin (81mg) daily is effective to prevent major adverse cardiovascular events and major adverse limb events in patients with PAD who are not at risk of increased bleeding.
6. Structured exercise is a core component of care for patients with PAD. It includes supervised exercise therapy and community-based programs.
7. Revascularization (endovascular, surgical, or hybrid) should be used to prevent limb loss in those with chronic limb-threatening ischemia and can be used to improve quality of life and functional status in patients with claudication not responsive to medical therapy and structured exercise.

10 Take Home Messages from report

8. Care for patients with PAD, and especially those with chronic limb-threatening ischemia, is optimized with delivered by a multispecialty care team.
9. Foot care is crucial for patients with PAD across all clinical subsets and range from preventative care and patient education to advanced care in the setting of chronic limb-threatening ischemia. Podiatrists and other specialists with expertise in foot care, wound healing therapies, and foot surgery are important members of the multispecialty care team.
10. The PAD National Action Plan outlines 6 strategic goals to improve awareness, detection, and treatment of PAD nationwide. Implementation of this action plan is recognized as a top advocacy priority by the writing committee.

10 Take Home Messages from report

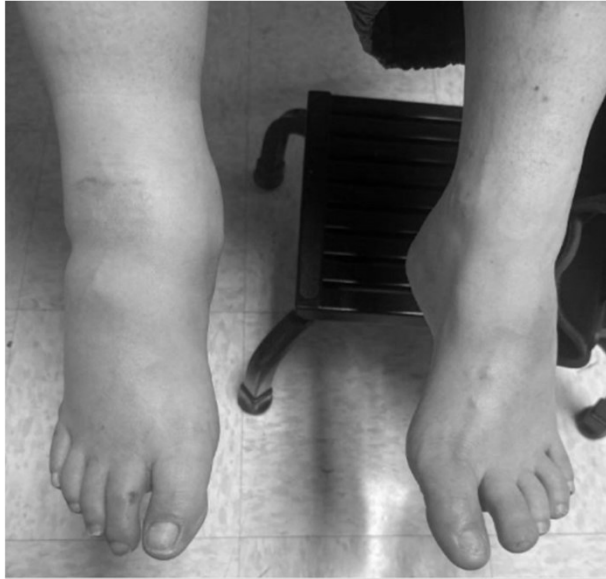

American Heart Association (www.heart.org)

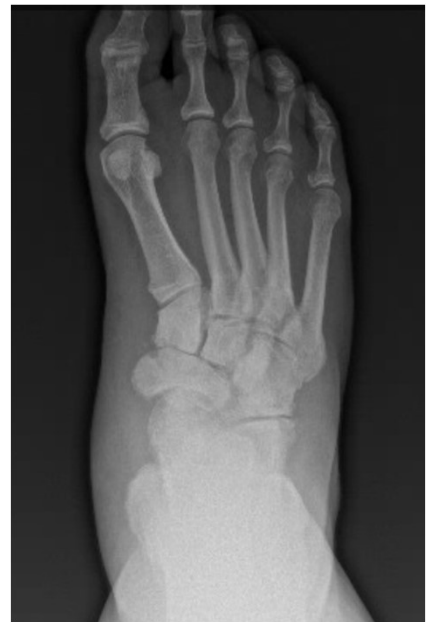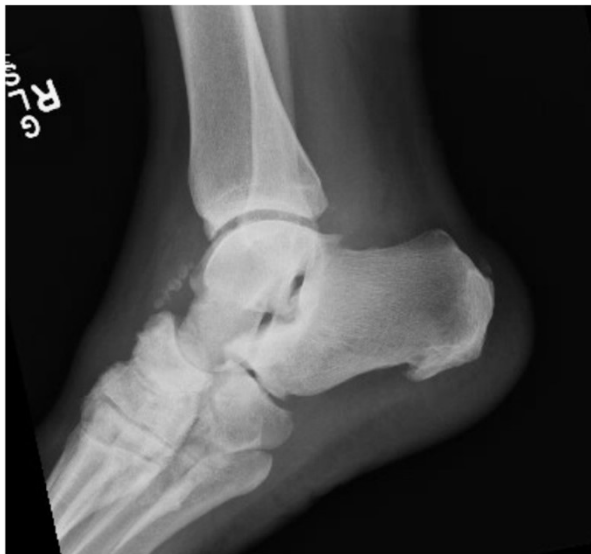Charcot neuroarthropathy

- Neuropathic conditions
 - Diabetic neuropathy
 - Alcoholic neuropathy, syringomyelia, spinal cord injury, syphilis
- Neurovascular vs neurotraumatic theories
- Red, hot, swollen joint
 - Can be from injury
 - Often non painful due to neuropathy

Charcot neuroarthropathy



Charcot neuroarthropathy



Charcot neuroarthropathy

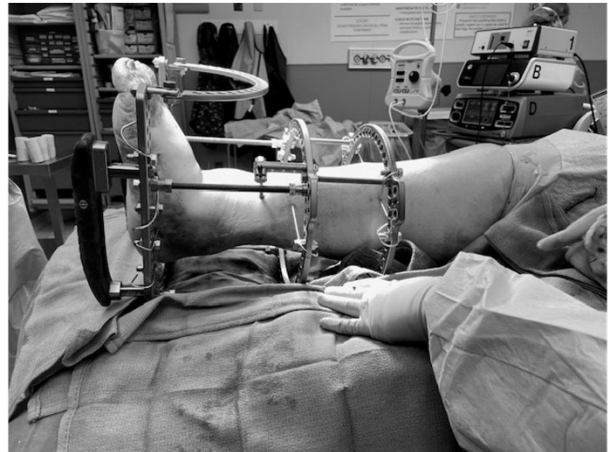
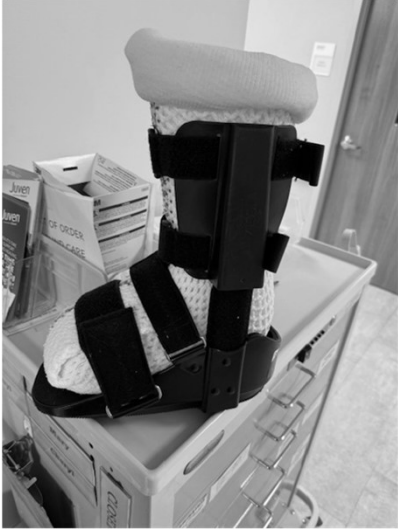- Eichenholtz Classification ^{29,30}
 - Stage 1 – Bone dissolution, subchondral osteopenia, fragmentation of bone with accompanying intra-articular loose bodies, and joint malignment due to ligament laxity
 - Stage II – Coalescence, debris absorption, subchondral sclerosis, periosteal bone formation, and fusion of larger bone fragments
 - Stage III – Reconstruction, remodeling of deformity with rounding and smoothing of bone fragments and fibrous ankyloses

Charcot neuroarthropathy

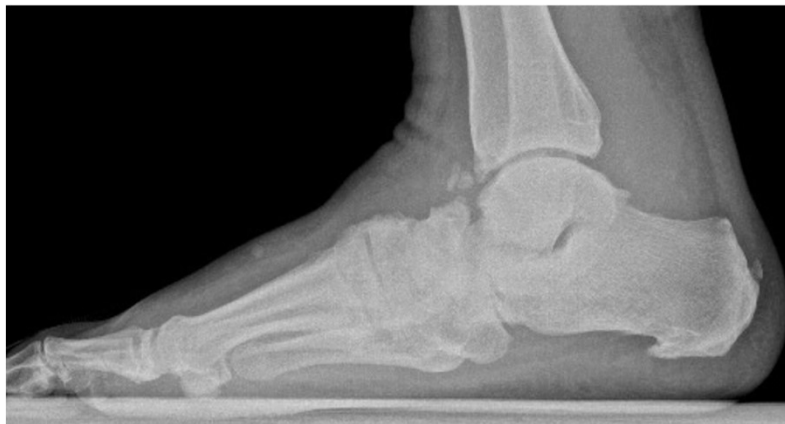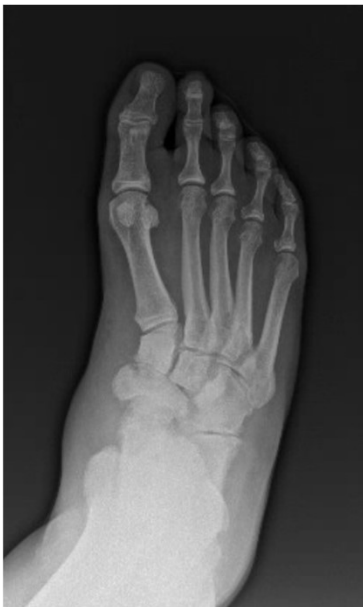- Goal is to get out of stage 0/I and into a more stable stage II/III
- Immobilization*
- Maintain a plantar grade foot
- Prevent ulcer and infection
- Control diabetes or underlying condition

Charcot neuroarthropathy

- Immobilization



Charcot neuroarthropathy



After 6 months of immobilization

References

- Gerbert J. Textbook of Bunion Surgery. Data Trace Publishing. 2012.
- Austin DW, Leventen EO. A new osteotomy for hallux valgus: a horizontally directed "V" displacement osteotomy of the metatarsal head for hallux valgus and met primus. *Clin Orthop Relat Res.* 1981; Jun;(157):25-30.
- Chandler LM. First metatarsal head osteotomies for the correction of hallux abducto valgus. *Clin Podiatr Med Surg.* 2014; 31(2):221-231.
- Martin DE, Blitch EL. Alternatives to the closing base wedge osteotomy. *Clin Podiatr Med Surg.* 1996; 13(3):515-531.
- Sammarco VJ. Surgical Strategies: Mau osteotomy for correction of moderate and severe hallux valgus deformity. *Foot Ankle Intl.* 2007;28(7):857-864.
- Dayton P, Feilmeier M, Kauwe M, Harschi J. Relationship of frontal plane rotation of first metatarsal to proximal articular set angle and hallux alignment in patients undergoing tarsometatarsal arthrodesis for hallux abducto valgus: A Case series and critical review of the literature. *J Foot Ankle Surg.* 2013; 52(3):348-354.
- Rettedal D, Lowery N. Proximal phalangeal osteotomies for hallux abductovalgus deformity. *Clin Podiatr Med Surg.* 2014; 31(2):213-220.
- Isham S. The Reverdin-Isham procedure for the correction of hallux abducto valgus: A distal metatarsal osteotomy procedure. *Clin Podiatr Med Surg.* 1991; 8(1):81-94.
- Magnan B, Bortolazzi R, Samaila E, Pezze L, Rossi N, Bartolozzi P. Percutaneous distal metatarsal osteotomy for correction of hallux valgus: Surgical technique (supplement). *J Bone Joint Surg.* 2006; 88(1):135-148.
- Nawoczenski DA, Baumhauer JF, Umberger BR. Relationship between clinical measurements and motion of the first metatarsophalangeal joint during gait. *J Bone Joint Surg.* 1999; 81(3):370-376.
- Camasta CA. Hallux limitus and hallux rigidus: clinical examination, radiographic findings, and natural history. *Clin Pod Med Surg.* 1996; 13(3):423-448.
- Craven J, Naismith A. Isolated Osteochondral defect of the first metatarsal head: A review of surgical treatment options and case report. *Foot and Ankle Surg: Techniques, Reports and Cases.* 2025; 5(1) 1-5.
- Black JR. Paronychia. *Clin Podiatr Med Surg.* 1995;12(2):183-7. PMID: 7600493.
- Lomax A, Thorton J, Singh D. Toenail paronychia. *Foot and Ankle.* 2016; 22(4): 219-223.
- Leggit J. Acute and Chronic Paronychia. *American Family Physician.* 2017; 96(1): 44-51.
- Centers for Disease Control and Prevention. Clinical guidance for Wound Management to Prevent Tetanus. 2025.
- Patzakis MJ, Wilkins J, Brien W, Carter V. Wound site as a predictor of complications following deep nail punctures to the foot. *West J Med.* 1989; 150(5): 545-547.
- Armstrong DG, Lavery LA, Quebedeaux TL et al. Surgical Morbidity and the risk of amputation due to infected puncture wounds in diabetic versus non diabetic adults. *J Am Podiatr Med Assoc.* 1997; 87(7):321-326.
- Aras MH, Miloglu O, Barutcuoglu C, Kantarci M, Ozcan E, Harorli A. Comparison of the sensitivity for detecting foreign bodies among conventional plan radiography, computed tomography and ultrasonography. *Dentomaxillofac Radiol.* 2010; 39(2):72-78.
- Haverstock B. Puncture wounds of the foot. *Clinics in Pod Med and Surg.* 2012; 29(2):311-322.
- Nigam PK, Syed HA, Saleh D. Tinea pedis. 2021 Jun 7 in StatPearls (internet). Treasure Island, FL: StatPearls Publishing; 2023.
- Vlahovic TC, Schleicher SM. Atlas of Lower Extremity Skin Disease. 2022. Springer Nature Switzerland AG.
- Norgren L, Hiatt WR, Dormandy JA et al. Inter-society consensus for the management of peripheral arterial disease (TASC II). *J Vasc Surg.* 2007; 45S:S5-67.
- Barshes NR, Flores E, Belkin M, et al. The accuracy and cost-effectiveness of strategies used to identify peripheral artery disease among patients with diabetic foot ulcers. *J Vasc Surg.* 2016; 64: 1682-1689.
- Marston WA, Davies SW, Armstrong B, et al. Natural history of limbs with arterial insufficiency and chronic ulceration treated without revascularization. *J Vasc Surg.* 2006; 44: 108-144.
- Mills JL, Conte MS, Armstrong DG, et al. The Society for Vascular Surgery Lower Extremity Threatened Limb Classification System: risk stratification based on wound, ischemia, and foot infection.(WIFI) *J Vasc Surg.* 2014; 59:220-234.
- Faglia E, Clerici G, Caminiti M, et al. Predictive values of transcutaneous oxygen tension for above the ankle amputations in diabetic patients with critical limb ischemia. *Eur J Vasc Endovasc Surg.* 2007; 33:731-736.
- DiDomenico LA, Ghai AK, et al. Charcot Neuroarthropathy. McGlamry's Foot and Ankle Surgery, 5th ed. Ch 38. 773-804. Wolters Kluwer 2022.
- Rosenbaum AJ, DiPreta JA. Classifications in brief: Eichenholtz classification of Charcot arthropathy, author information. *Clin Orthop Relat Res.* 2015; 473(3): 1168-1171.
- Yu GV, Hudson JR. Evaluation and treatment of stage 0 Charcot's neuroarthropathy of the foot and ankle. *J Am Podiatr Med Assoc.* 2002; 92(4):210-220.



Common Foot and Ankle Conditions

Said Atway, DPM

Associate Clinical Professor

Department of Orthopaedics

Division of Podiatry

The Ohio State University Wexner Medical Center

MedNet21

Center for Continuing Medical Education

THE OHIO STATE UNIVERSITY
WEXNER MEDICAL CENTER

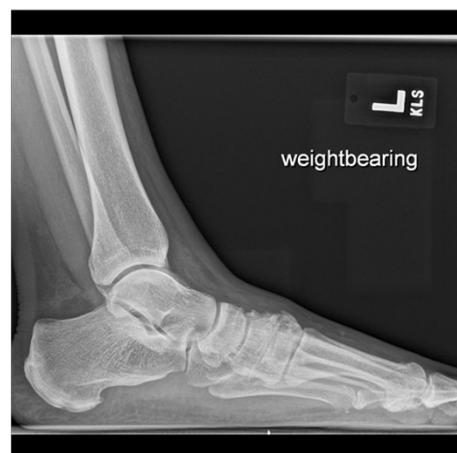Objectives

- Common foot and ankle conditions
 - Plantar Fasciitis
 - Retrocalcaneal Exostosis
 - Neuroma
 - Digit deformities
- Basic evaluation and overview
- Basic treatment

Heel Pain

- Plantar fasciitis
- Heel spur syndrome
 - Misnomer
- Post static dyskinesia
- Plantar heel pain
 - Medial calcaneal tubercle
- 4-7% of the population

• Thomas MJ, Whittle R, Menz HB, et al. Plantar heel pain in middle-aged and older adults: population prevalence, associations with health status and lifestyle factors, and frequency of healthcare use. *BMC Musculoskelet Disord* 2019;20:337.



Etiology

- Flat foot
- Equinus
- Overpronation
- Weight gain
- Exercise regimen
- Poor shoe gear
- Barefoot walking

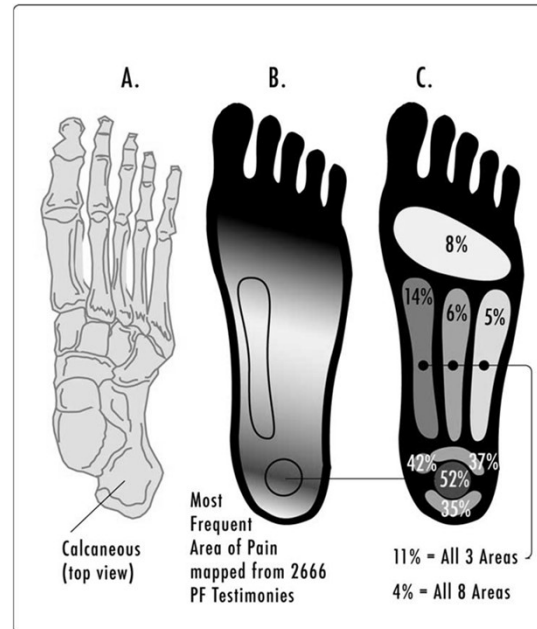
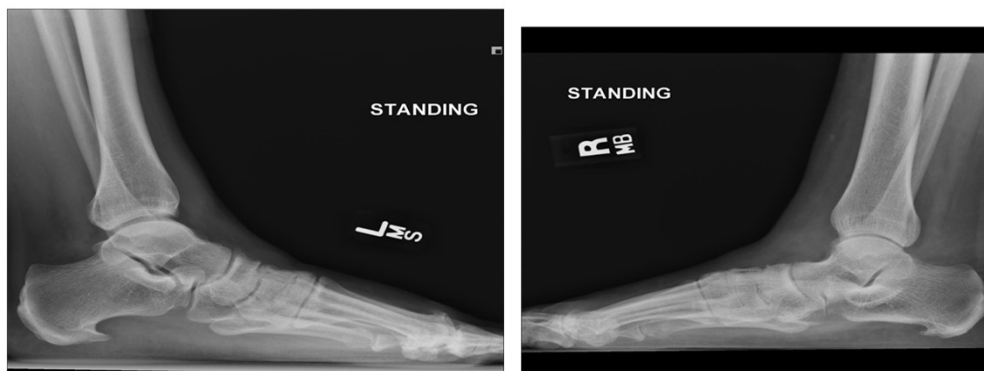

Image from Wikipedia

Spur Comparison



Physical Exam

Pronated foot

Obese

Edema to plantar/medial heel

Pain with palpation

- Lateral compression

- Subjective findings
- Post-static



Analysis of Plantar Fasciitis Websites Using the DISCERN Instrument

Deana L. Lewis, DPM¹, Sean Reyes, DPM¹, Christy Ortigas, RN², Said Atway, DPM¹

1. The Ohio State University Wexner Medical Center, Department of Orthopedics Division of Podiatry, Columbus, OH

2. University of Nevada Las Vegas, Las Vegas, NV

Cureus
Part of SPRINGER NATURE

Open Access Original Article

Analysis of Plantar Fasciitis Videos on YouTube: Quality and Reliability Assessment

Ahmet Burak Satılmış¹, Tolgahan Cengiz¹

1. Orthopaedics and Traumatology, Taşköprü State Hospital, Kastamonu, TUR

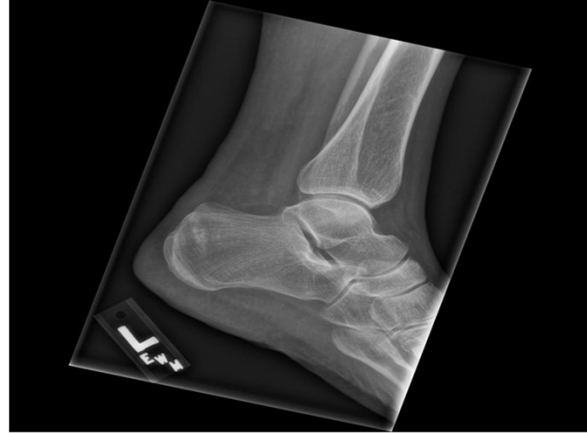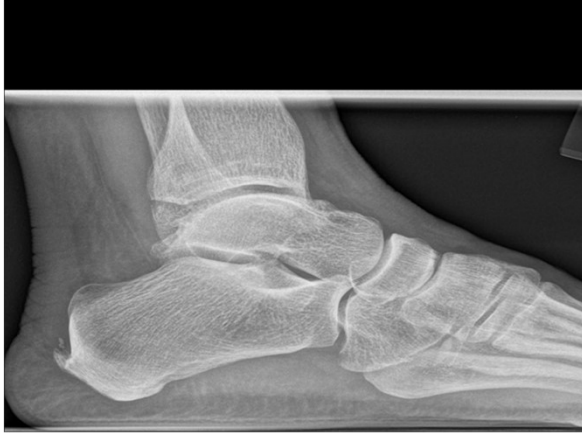Corresponding author: Tolgahan Cengiz, tolgahancengiz@hotmail.com

Review began 02/06/2025
Review ended 02/13/2025
Published 02/14/2025

© Copyright 2025

Satılmış et al. This is an open access article distributed under the terms of the Creative Commons Attribution License CC-BY 4.0.,

Not Plantar Fasciitis



Treatment

80% of patients improve in 12 months

Stretching

Home cryotherapy

Avoid barefoot walking

NSAIDs

Activity modifications

Support

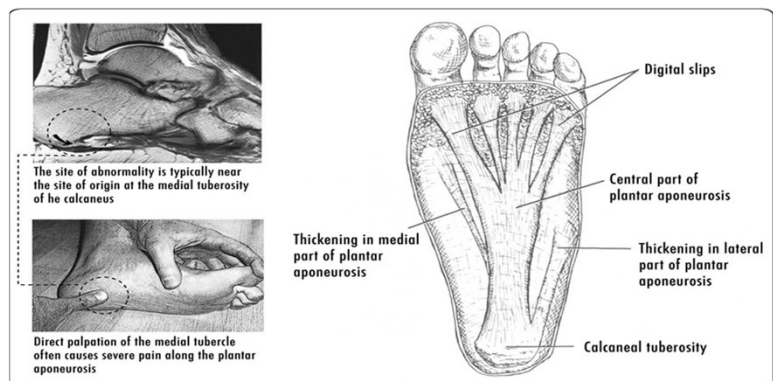


Image from Wikipedia

Secondary Treatment

Injections

- Steroid

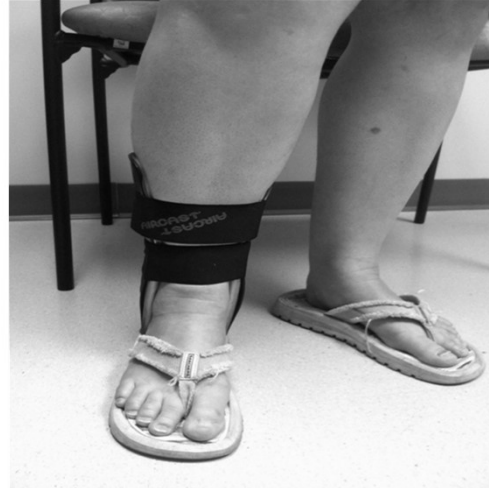Night splint

- Windlass

Immobilization

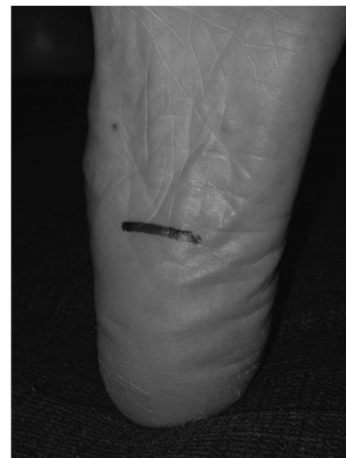Custom orthotics

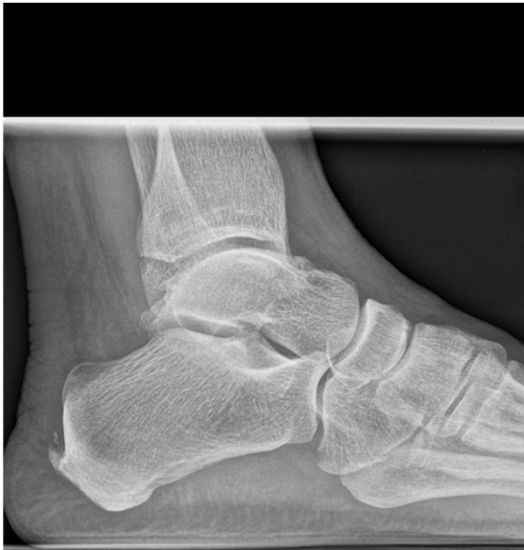Formal physical therapy



Advanced workup and treatment

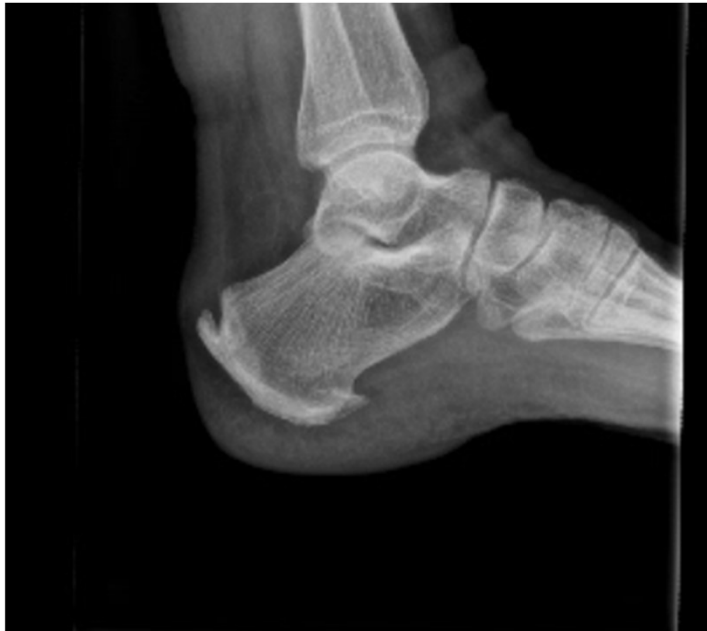- Imaging
 - US and MRI
- Surgery
 - Failed conservative treatment >6 mos
 - Plantar fasciotomy
 - ESWT (extracorporeal shockwave therapy)
 - Coblation





- Retrocalcaneal Exostosis
- Haglands Deformity
- Insertional Achilles tendinitis


Posterior spur



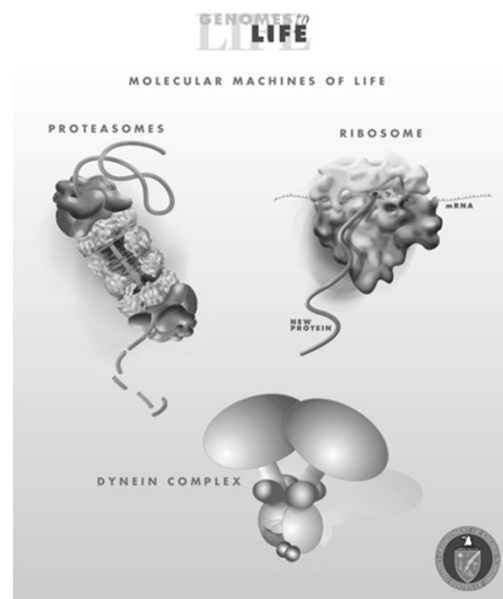
Etiology

- Similar to Plantar fasciitis
- Intratendinous spur
- Haglund's deep to the achilles

- Patients typically report:
- Dull, aching pain at the posterior heel
- Tenderness and swelling exacerbated by activity or footwear
- Palpable thickening or hardness near the Achilles insertion
- Pain during initial steps after rest (e.g., morning pain)



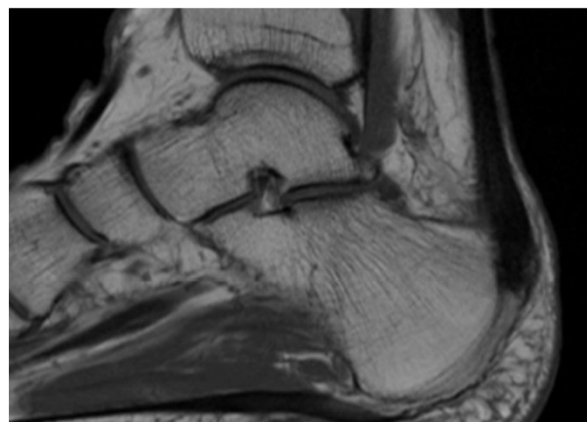
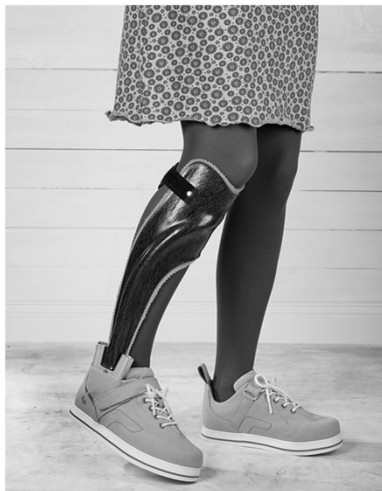- Caused by **chronic mechanical stress** from a short or tight Achilles tendon pulling on its calcaneal insertion.
- This stress stimulates **Wolff's Law**-driven bone formation.
- Risk factors include:
 - Obesity
 - Poor conditioning
 - Certain footwear (e.g., rigid heel counters)
 - Athletic activity
 - Female gender (possibly due to shoe styles)



Conservative treatment

- Alfredson Protocol
- Physical therapy
- Bracing
- Shoe modifications
- Surgical Excision
- Minimally invasive
- ESWT
- Arthroscopic
- Open

Bracing and Imaging



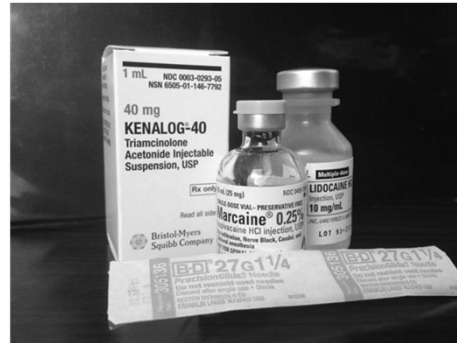Neuroma/Morton's Neuroma

Burning pain

Numbness/Tingling

Sharp radiating pain

“Wrinkled-sock sensation”



Exam

- Pain with palpation
- Mulder's click
- Radiating sensation
- Radiographs
 - R/O differentials
- Ultrasound
- MRI

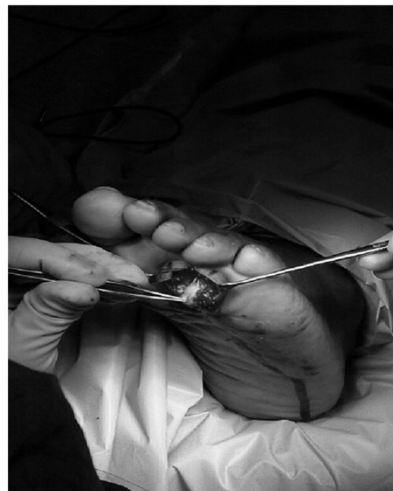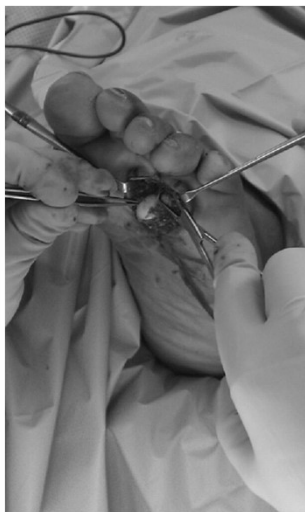


Treatment

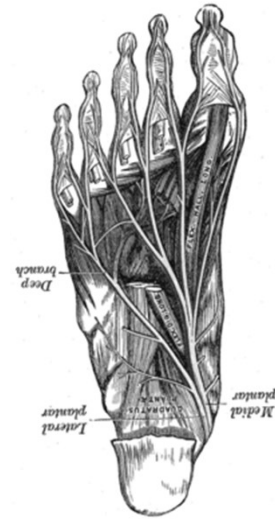- Shoe modifications
- Orthotics
- Padding
- Injections
 - Steroid
 - EtOH
- Surgery
 - Excision
 - Decompression



Neuroma Excision vs. Neurolysis



- Neuroma traditionally thought of as a growth of nerve.
- Nerve entrapment



0198-0211/97/1805-0284\$03.00/0
 FOOT & ANKLE INTERNATIONAL
 Copyright © 1997 by the American Orthopaedic Foot and Ankle Society, Inc.

Treatment of Morton's Neuroma by Neurolysis

Ben Okafor, F.R.C.S.(Orth.),* Gurd Shergill, F.R.C.S.,† and John Angel, F.R.C.S.,‡
 Stanmore, Middlesex, England

Article

Neurectomy versus Neurolysis for Morton's Neuroma

Carlos Villas, MD, PhD, Borja Florez, MD, and Matias Alfonso, MD, PhD

REVIEW ARTICLE - PERIPHERAL NERVES



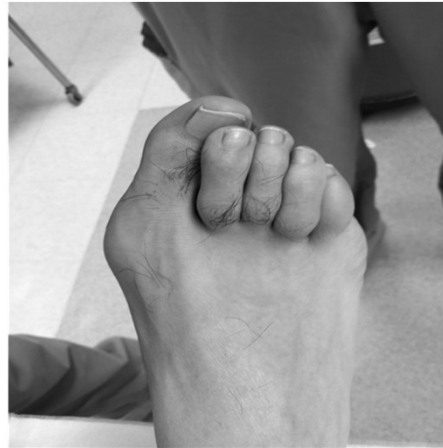Treating Morton's neuroma by injection, neurolysis, or neurectomy:
 a systematic review and meta-analysis of pain
 and satisfaction outcomes

Victor M. Lu¹ · Ross C. Puffer¹ · Megan C. Everson¹ · Hannah E. Gilder¹ · S. Shelby Burks² · Robert J. Spinner²

Received: 2 December 2019 / Accepted: 23 January 2020 / Published online: 13 February 2020
 © Springer-Vorlag GmbH Austria, part of Springer Nature 2020

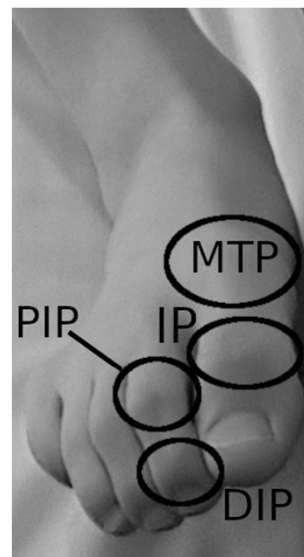
Digital Deformities

- Hammertoe
- Claw toe
- Mallet toe
- Crossover toe
- Adductovarus
- Contracture

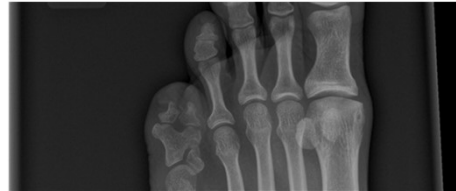
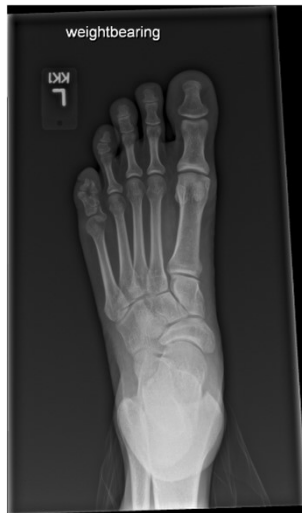
Exam

- Radiographs
- Pain with palpation
- Callus
- ROM
- Stability/push up/WB

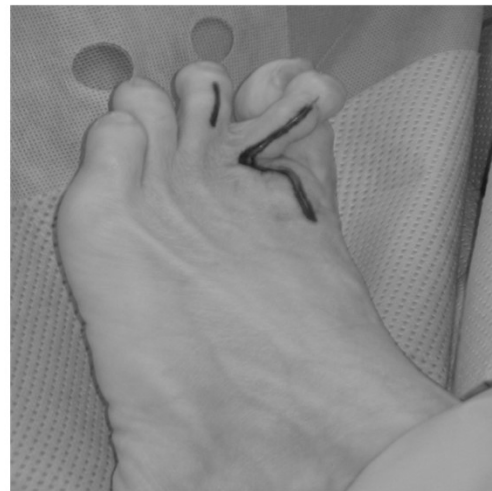

Polydactyly



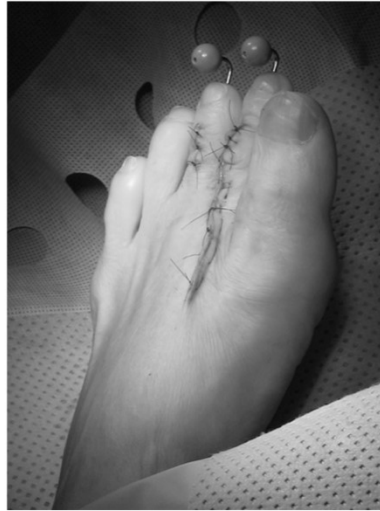Conservative Treatment

- Shoe modifications
- Padding
- Debridement
- Taping
- Injections



Surgery

- Arthroplasty
- Arthrodesis
 - Fixation
- Osteotomy
- Tendon transfer
 - Soft tissue balance



Conclusion

- Exhaust conservative treatment
 - Shoe modifications
- Realistic goals
 - Patient expectations
- Surgical treatment options

